

## Anterior Maxillary Segmental Distraction: is it A Better Solution For Cleft Patients with Hypoplastic Maxilla? And Which Has A Better Outcome Extraoral or Intraoral Bone Distractors?

Aida M. Mossaad<sup>1</sup>, Susan A. Hassan<sup>2</sup>, Hatem H. Al Ahmady<sup>3</sup>,  
Eman H. Aboul Ezz<sup>4</sup>, Moustapha A. Abdelrahman<sup>5</sup>

<sup>1</sup>Researcher Of Oral & Maxillofacial Surgery At National Research Center

<sup>2</sup>Professor Of Oral & Maxillofacial Surgery & Head Of The Department Al Azhar University Girls' Branch

<sup>3</sup>Professor At Oral & Maxillofacial Surgery Department, Al Azhar University Girls' Branch

<sup>4</sup>Professor Of Orofacial Genetics At National Research Center

<sup>5</sup>Researcher Of Orthodontics At National Research Center

**Abstract:** The aim of this study was to compare between extraoral and intraoral distraction for anterior maxillary advancement in patients with maxillary deficiency associated with cleft lip and palate (CLP).

**Materials & Methods:** This study included twelve nonsyndromic patients suffering from maxillary hypoplasia who were randomly selected and divided into two groups. Group I included six patients treated with extraoral device, in group II six patients were treated with intraoral device. All patients received preoperative orthodontic treatment for teeth alignment as well as creating spaces for osteotomies. Lateral cephalogram measuring SNA & ANB angles and 3D computed tomography CT were used to evaluate soft tissue and hard tissue changes postoperatively compared to preoperatively. Computer assisted surgical simulation (CASS) software Materialize Interactive Medical Image Control System (MIMICS) version 10.1 helped in obtaining a stereolithographic 3D model used for preoperative surgical planning.

**Results:** Though maxillary advancement was evident in both groups, a significant change was observed in cases with extraoral distraction. The lateral cephalometry tracing revealed SNA mean have increased in group A from  $(75.3 \pm 3.7)$  preoperative to  $(81.8 \pm 5.4)$  postoperative value after device removal with P value 0.005\*\* showing high statistical significance. ANB mean value increased from  $(-2.5 \pm 1.0)$  preoperative to  $(4.0 \pm 3.6)$  postoperative value after device removal with P value 0.005\*\* high statistical significance. While SNA mean have increased in group B who were treated by intraoral device from  $(75.3 \pm 3.4)$  preoperative value to  $(80.2 \pm 3.8)$  postoperative value after device removal with P value 0.001\*\* high statistical significance and ANB mean from  $(-2.3 \pm 0.5)$  preoperative to  $(2.5 \pm 1.0)$  postoperative value after device removal with P value 0.001\*\* high statistical significance. However cases with extraoral distraction showed more complications and less patients acceptance.

**Conclusion:** Hence anterior maxillary segmental distraction (AMSD) is a better choice for treatment of maxillary hypoplasia associated with CLP rather than conventional orthognathic surgery

**Keywords:** Anterior maxillary segmental distraction, Maxillary hypoplasia, Computer assisted surgical simulation.

### I. Introduction

Maxillary hypoplasia is common finding in patients suffering from CLP. Conventionally it has been corrected by orthognathic surgery advancement technique (Le Fort I) osteotomy since 1970s.<sup>(1)</sup> However this technique has got many drawbacks as negative effect on velopharyngeal incompetence (VPI), high post surgical relapse rates, excessive tissue scarring, palatal exposure and less vascular supply with higher risk of bone necrosis.<sup>(2)</sup> Distraction osteogenesis has opened a new perspective in treatment of CLP since 1990s.<sup>(3)</sup> Distraction osteogenesis allows progressive movement of the maxilla rather than immediate transposition giving a better chance of skeletal and soft tissue adaptation.<sup>(4,5)</sup> Advancement of hypoplastic maxilla has been a point of research since decades, but for the past few years the technique of advancement of only the anterior maxillary segment has been a subject of interest. In 2004 Karakasis & Hadjipetrou introduced the idea of anterior maxillary advancement by distraction.<sup>(6)</sup> The present study utilized the idea of benefits of Anterior Maxillary Segmental Distraction (AMSD) for maxillary advancement and treatment of anterior cross bite over the classic Le Fort I osteotomy.<sup>(7-9)</sup> The combined benefits that were achieved by such technique was to minimize future relapse as well as to preserve the (VPI) already present without further violation<sup>(10-11)</sup>. Tooth borne distractors showed easier application taking anchorage from teeth, however they caused dentoalveolar damage such as teeth tilting, periodontal stress and bone fenestration.<sup>(12-14)</sup> In this study a comparison was made between extraoral

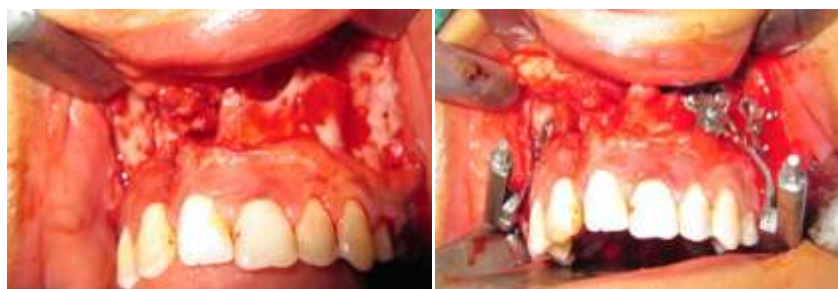distraction and intraoral distraction.<sup>(15)</sup> Extraoral bone distractors showed superior results as regard maxillary advancement however it caused more complications and less patients tolerance. While the intraoral bone distractors showed less maxillary advancement and more patients acceptance.<sup>(16-18)</sup> The Computed tomography 3DCT and lateral cephalometry had an essential role for obtaining a 3D model for preoperative surgical planning.<sup>(19-20)</sup> as well as checking the osteotomy design and its diagnostic role in preoperative assessment of bone density and detection of cleft site or any other anatomical abnormalities and mostly confirmation of bone ossification postoperatively.<sup>(21)</sup>

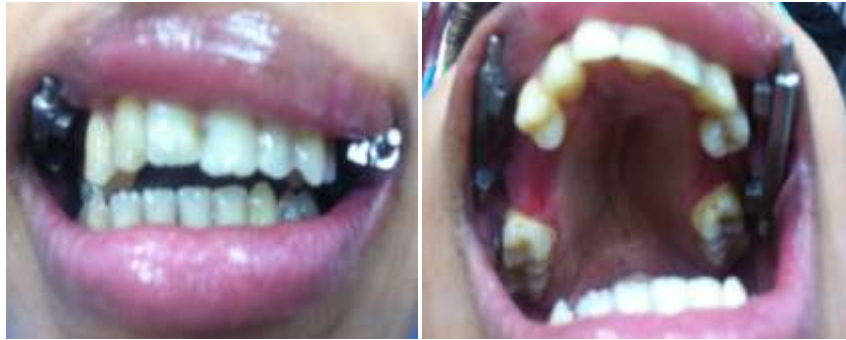## II. Patients & Methods

This study included twelve patients, 2 females & 10 males age ranging from 13 to 23 years with mean 16.5 years having non syndromic CLP and maxillary hypoplasia who needed maxillary advancement. Patients were randomly selected from patients who attended the Department of Oral and Maxillofacial Surgery, Faculty of Dental Medicine, Al Azhar University for Girls, Orofacial Genetics Department National Research Centre and Cleft Care Clinic Faculty of Oral & Dental Medicine, Ain Shams University from March 2011 till March 2015. All patients were informed about the research and they signed a consent to participate in the study. The local ethical committee of ethics at National Research Center Giza Egypt have approved the study. Inclusion criteria for patients eligible in this study suffering from maxillary hypoplasia and having anterior cross bite with no bony lesions and are systemically free and did not undergo previous advancement surgeries. Patients were distributed randomly among two groups.

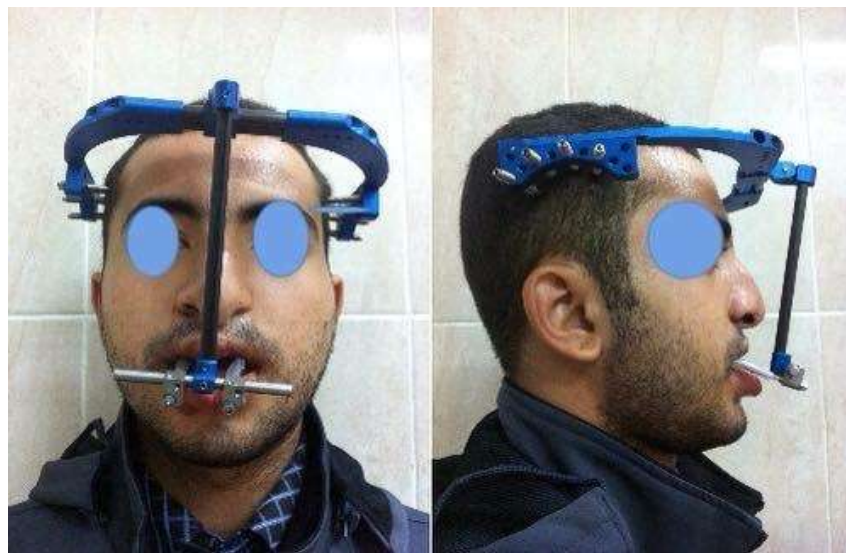Group I included 6 patients who were treated with extraoral bone distractor (Blue device) by Lorenz.<sup>6</sup> Fig (1) and Group II including 6 patients who were treated with intraoral bone distractor (Liou)<sup>7</sup> device by Martin. Fig (2) The alveolar cleft was grafted at 9-11 years. All patients had orthodontic preparation one year prior to surgery for teeth alignment and creating proper spaces for osteotomy lines. Preoperative evaluation included: medical and dental history, extraoral and intraoral photographs, dental casts and radiographs including (digital panorama, lateral cephalograms and multislice 3DCT) with the aid of CASS software MIMICS version 10.1<sup>8</sup> Fig (3) to obtain a 3D model for preoperative surgical planning & prebending of the intraoral device to save time & effort during the surgery. Fig (4) And lateral cephalometry tracing measuring SNA of the maxilla and ANB angles.

**Surgical procedures:** The surgery was carried under general anaesthesia with complete aseptic conditions. A vestibular incision was made from molar to molar. Two vertical osteotomy lines mesial to the first molars bilaterally connected with a horizontal osteotomy and a palatal tunnel approach to mobilize the anterior maxillary segment. In group I the extraoral device was fixed with titanium miniplates & screws to the anterior region of the maxilla taking extraoral anchorage from a cranial halo fixed to the cranium with intracranial screws. While in group II the intraoral device was fixed to the anterior region of the maxilla and zygomatic buttress with titanium miniscrews. Complete mobilization of the anterior maxillary segment was checked and the distractors were activated for few millimeters to check accuracy of maxillary movement. The wound was closed with continuous suture. Postoperative care and medications were applied. After a latency of 5 days. Distraction was initiated at the rate of 1 mm/day in two rhythms until the predetermined maxillary advancement was achieved. The appliance was kept in place for the period of 12–14 weeks following the activation phase for complete consolidation. After the device removal a series of photographs were taken, also the radiographic evaluation through CT showed amount of bone regenerated and lateral cephalograms showed an increase in SNA angle denoting maxillary advancement. Follow up period lasted for a year postoperatively. All patients were clinically assessed and evaluated everyday during the first week, every week during the first 3 months and once monthly for the following 9 months. A comparison was made between both distractors as regard: 1-Ease of application, 2-Degree of maxillary advancement, 3- Complications (damage to adjacent teeth, lip injury and injury of scalp), 4-Quality of bone formation after consolidation period, 5-Amount of postoperative relapse, 6-Soft tissue changes and 7-Patients acceptance. Statistical analysis was made using paired t-test & Chi square test for quantitative analysis. P values less than 0.5 were considered statistically significant.

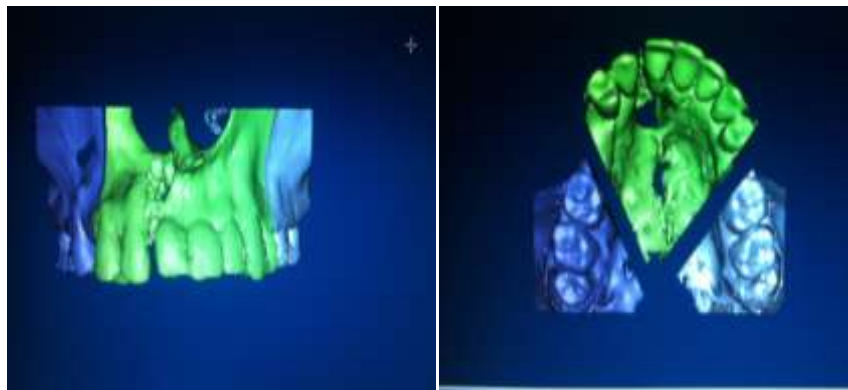




**Fig (1)** showing intraoral bone distractor



**Fig (2)** showing extraoral bone distractor with cranial halo & intracranial screws



**Fig (3)** showing preoperative surgical planning using MIMICS 10.1 software



**Fig (4)** showing 3D model and prebending of intraoral distractor

**III. Results**

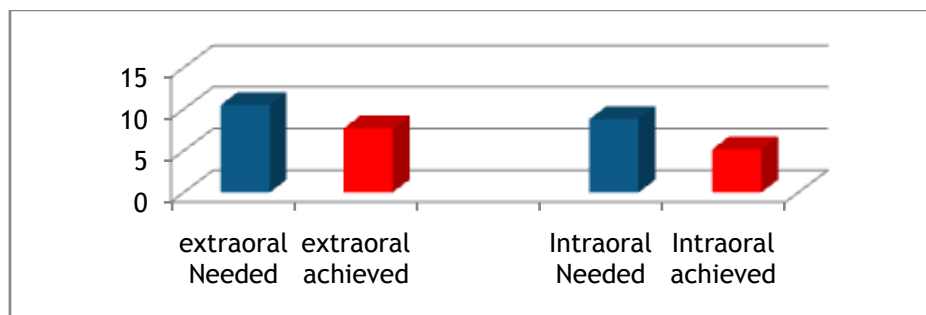
This study included 12 young adolescent patients, 10 males and 2 females (mean age  $16.8 \pm 3.3$ ) suffering from hypoplastic maxilla and anterior cross bite. Five patients had bilateral complete cleft lip palate BCLP, while seven patients had unilateral complete cleft lip and palate UCLP. All patients were followed strict oral hygiene measures and soft diet instructions. Few patients showed mild edema, pain and nasal bleeding which resolved a couple of days postoperatively. Few patients experienced mild type of pain by the end of the first week during activation due to pressure created on bone from distraction force. All patients removed the devices after the completion of consolidation period that lasted for twelve weeks except two cases who removed the device earlier for social reasons and placed plates and screws for maxillary fixation. During removal of the devices a flap was made for plates exposure. It was observed that the free segment was clinically stable and the new bony gap was evident mesial to the first molar bilaterally as a result of distraction osteogenesis and this was confirmed with postoperative radiographic evaluation. Eleven patients have responded to the technique while one patient with extraoral distractor failed to respond to the distraction after the surgical procedures were performed to separate the maxilla twice.

The patient was treated later on with orthodontic expander device before complete consolidation. One case showed insufficient amount of maxillary advancement and canting of maxilla with intraoral device. Two cases showed overcorrection that resulted in slight prognathism with extraoral device. Statistical analysis using the paired T-test and Chi square test for quantitative analysis. The lateral cephalogram tracing revealed that the SNA mean have increased in group A who were treated by extraoral device from ( $75.3 \pm 3.7$ ) preoperative value to ( $81.8 \pm 5.4$ ) postoperative value after device removal with P value 0.005\*\* showing high statistical significance. ANB mean value increased from ( $-2.5 \pm 1.0$ ) preoperative value to ( $4.0 \pm 3.6$ ) postoperative value after device removal with P value 0.005\*\* high statistical significance. While SNA mean have increased in group B who were treated by intraoral device from ( $75.3 \pm 3.4$ ) preoperative value to ( $80.2 \pm 3.8$ ) postoperative value after device removal with P value 0.001\*\* high statistical significance and ANB mean from ( $-2.3 \pm 0.5$ ) preoperative value to ( $2.5 \pm 1.0$ ) postoperative value after device removal with P value 0.001\*\* high statistical significance. Generally the extraoral distractor turned out to have higher value than the intraoral distractor. Table (1) Fig (5) The extraoral device showed more postoperative relapse due to increased amount of maxillary advancement segment with P value  $<0.05$  than the intraoral device resulting from excessive scarring of soft tissue from previous surgeries. Fig (6). Both devices showed similar quality of bone formed after distraction at the end of consolidation phase.

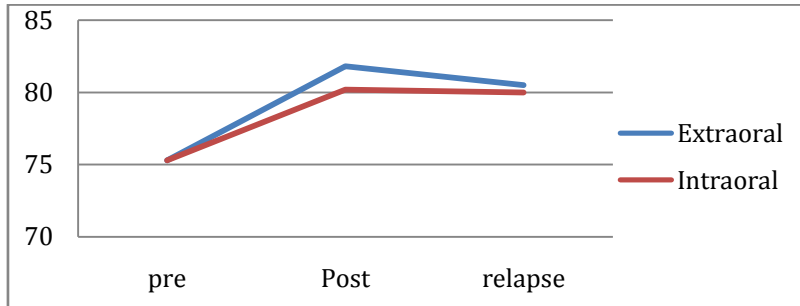
The extraoral distractor caused more complications for patients as regard loss of adjacent teeth, inflammation in the scalp from intracranial screws and lip injuries that was 50 % of cases also the amount of damage of adjacent teeth occurred was 33.3 %. while intraoral device caused soft tissue injuries for the lip 16.7 % of cases and 0% of cases lost their teeth. The patients have accepted the intraoral device Fig (7-12) than the extraoral device Fig (13-18) as it is more bulky and the intracranial screws were uncomfortable. Generally most patients showed facial esthetic improvement and better occlusion with fullness of lips and cheeks also they have showed psychological satisfaction.

Variable	Extraoral (n=6)				Intraoral (n=6)			
	Pre	Post	T	P	Pre	Post	T	P
SNA	75.3±3.7	81.8±5.4	4.867	0.005**	75.3±3.4	80.2±3.8	10.127	<0.001* *
SNB	77.8±3.3	77.8±3.3	0.0	1.0	77.7±3.3	77.7±3.3	0.0	1.0
ANB	-2.5±1.0	4.0±3.6	4.867	0.005**	-2.3±0.5	2.5±1.0	10.127	<0.001* *

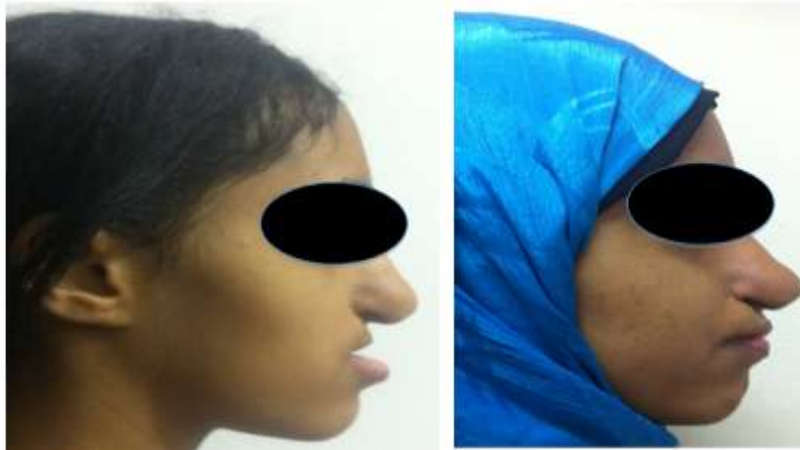**Table (1):** A comparison between preoperative & postoperative lateral cephalometry tracing (SNA, SNB, ANB)



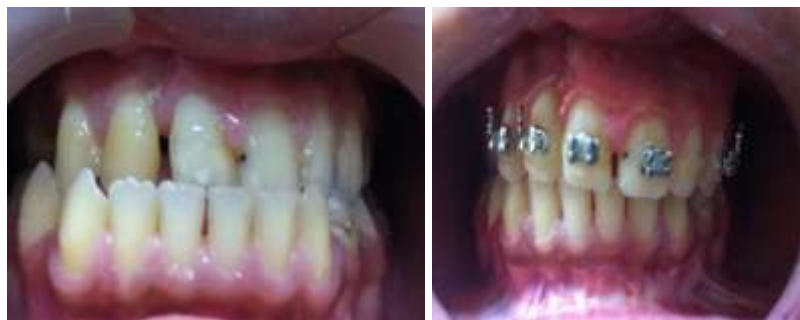**Fig (5)** A comparison between extraoral and intraoral device as regard amount of maxillary advancement needed & achieved postoperatively.



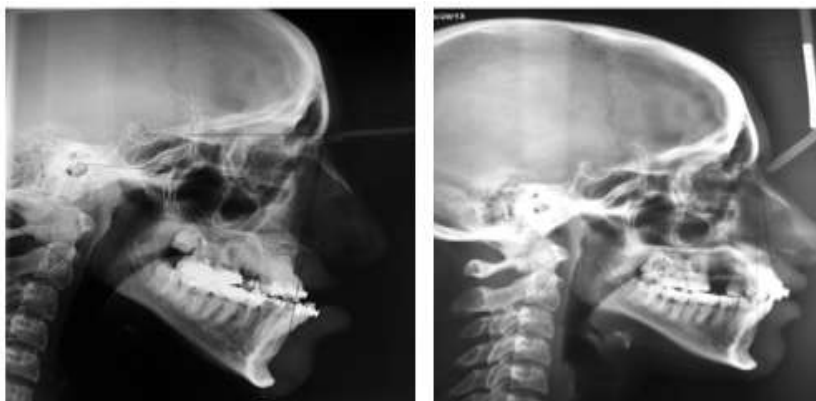**Fig (6)** A Comparison between extraoral and intraoral device in postoperative and relapse values as regard SNA point with lateral cephalometry tracing



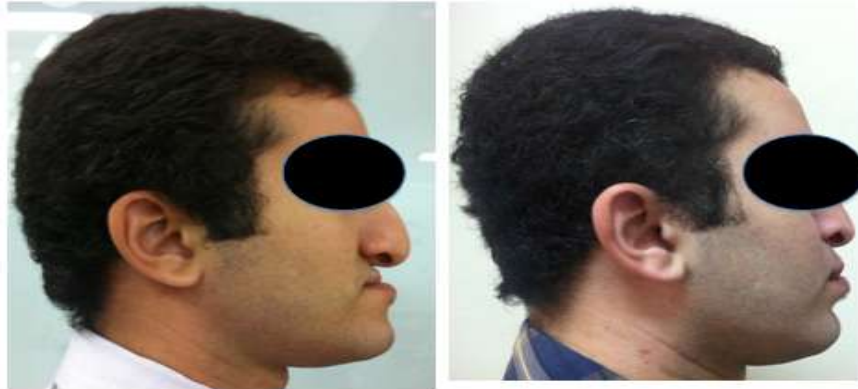**Fig. (7)** Showing preoperative profile, **Fig (8)** showing postoperative profile



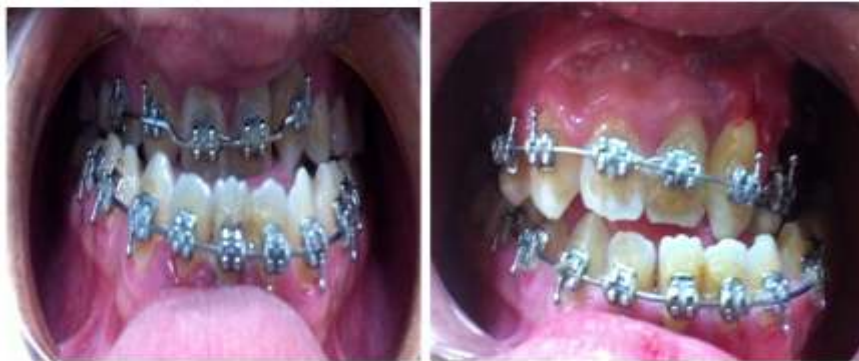**Fig (9)** showing preoperative occlusion **Fig (10)** showing postoperative occlusion



**Fig (11)** showing preoperative lat ceph. **Fig (12)** showing postoperative lat. ceph

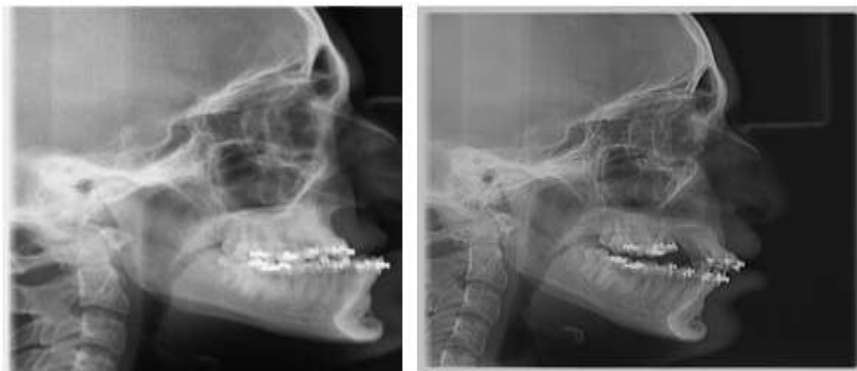

**Fig. ( 13 )** showing preoperative profile, **Fig ( 14 )** showing postoperative profile



**Fig (15)** showing preoperative occlusion,

**Fig ( 16 )** showing postoperative occlusion



**Fig(17)** showing preoperative lat ceph,

**Fig ( 18 )** showing post operative lateral ceph.

#### **IV. Discussion**

Our study included twelve nonsyndromic cleft patients with hypoplastic maxilla and normal mandible with anterior cross bite who did not undergo previous maxillary advancement surgeries. We chose to work for patients above the age of thirteen to avoid mixed dentition phase and to witness the canine eruption. The present study utilized the idea of benefits of anterior maxillary segmental osteotomy followed by distraction osteogenesis for premaxillary advancement and correction of anterior cross bite rather than the classic Le Fort I osteotomy. The combined benefits that were achieved by such technique was to minimize future relapse as well as to preserve the VPI condition without worsening using either intraoral or extraoral bone distractors.<sup>(21)</sup>Block et al.<sup>(22)</sup> in 1994 performed the first successful clinical application of (AMSD) using an intraoral tooth-borne distractor on dogs. While Dolanmaz et al<sup>(23)</sup> in 2003 did the first attempt on humans using tooth-borne device taking anchorage from teeth and reported its harmful effects on the dental structure. Karakasis et al<sup>(6)</sup> in 2004 did the first attempt in using the bone-borne distractor in cleft patients with anterior maxillary segmental distraction for advancement of hypoplastic maxilla facing more challenges due to soft tissue tightness from previous scars than normal patients. In the current study we used the bone-borne devices taking anchorage from

the zygomatic bone similarly to Van Stickles et al<sup>(17)</sup> who used bone-borne distractor for anterior hypoplastic maxillary advancement for correction of class III malocclusion in cleft patients.

The results were encouraging which turned out to be better than the tooth-borne devices taking anchorage from dental structures especially in cleft patients with more challenges. In the present study our results showed highly statistically significant changes regarding the tracing points (SNA and ANB) values in both groups of patients comparing preoperative and postoperative results. This was in accordance with Wang X et al<sup>(8)</sup> who observed marked elevation in (SNA and ANB) values postoperatively after maxillary advancement in their study. Meanwhile our results showed that the extraoral device was more efficient in achieving more maxillary advancement. Similar results were reported by Polley et al.<sup>(15)</sup> who compared extraoral versus intraoral bone devices as regard amount of maxillary advancement achieved. We were able to achieve correction of crossbite in most cases except for three cases who used intraoral device which was insufficient in reaching the same results as the extraoral device. The amount of maxillary advancement turned out to be less than the expected amount for cases with intraoral device due to the loss of the device power wasted in pulling the excessive scarred soft tissue in addition to the device limited range of movement compared to normal cases with maxillary retrusion. Same findings were reported by Harada et al.<sup>(24)</sup> who used more rigid devices as a modification for cleft lip and palate cases in his studies. Liou J<sup>(18)</sup> in 2009 introduced the techniques of intraoral distraction of segmental osteotomy and orthodontic management for solving a wide alveolar cleft, with miniscrews in 21 patients. All clefts were successfully approximated, and the 4- to 5-year follow up results were shown to be stable.

In this study the Liou device was used for intraoral distraction bilaterally for maxillary advancement. The Blue extraoral device was less accepted by patients especially the females. Patients have complained from intracranial screws and discomfort as regard sleeping, showering and fitting clothes besides the annoying appearance and impaired social activities. Also lip injuries resulted in some cases from extraoral rods that was overcome by covering the metallic parts with catheter rubber tubes. However the extraoral device had got its surgical benefits as easier placement of the device that was achieved with less intraoperative time without the need for preoperative planning with 3D surgical models. Also providing a better range of activation that permitted increased amount of maxillary advancement than the intraoral device. An important advantage of the extraoral device was being multidirectional allowing different vectors of movement.

This helped us much in adjusting the parallelism as well as the vectors of distraction postoperatively especially that we have experienced a counter clock rotation of the maxilla which resulted in open bite in a couple of cases which was solved by repositioning of the rods and using elastics while the bone was still soft.<sup>(25-26)</sup> However the intraoral device caused some damaging effect on adjacent teeth that resulted from drilling for the screws for the device plates fixation. As from the surgical point of view the intraoral device needed adequate amount of bone for its insertion. Moreover the device has got certain limitations as regard being unidirectional that is why it required proper placement and adjustment of parallelism intraoperatively as the vectors could not be modified postoperatively. In addition the device provides a limited range of activation which proved to provide insufficient amount of advancement of the maxilla that was minimal to moderate.<sup>(27-28)</sup> The orthodontic treatment was mandatory for our present study in relation to other studies involving premaxillary advancement. It was performed in two stages, a one year preoperative preparation for proper teeth alignment and leveling, also for creation of gaps anterior to the first molar bilaterally being the future planned site of osteotomy as well as a year postoperative for teeth alignment, relief of crowding and correction of remaining anterior cross bite.

Also we did preoperative palatal expansion for few cases to overcome maxillary transverse collapse.<sup>(29-30)</sup> Significant changes were observed in hard tissue as well as soft tissue profile with highly significant results postoperatively as regard the nasal tip, the alar base, the lip position compared to preoperative records clinically and radiographically. The amount of postoperative relapse that occurred in some of the cases could have resulted from excessive scarring and fibrosis of lips especially found in cleft patients or a big amount of premaxillary advancement achieved. It has been observed that the amount of postoperative relapse was directly related to the amount of maxillary advancement.<sup>(27)</sup> The digital multi slice 3DCT scan had an essential role in our study for preoperative surgical planning as regard assessment of bone density in addition to its diagnostic role in preoperative detection of cleft site or any other abnormalities and mostly confirmation of ossification six months post operatively. This is in accordance with Gateno et al<sup>(31)</sup> who was the first to use 3D models with computer surgical assisted planning.

## **V. Conclusion**

Anterior maxillary segmental distraction is a recent modification of Le Fort I maxillary advancement avoiding the violation of VPI. Significant soft tissue and hard tissue changes were clearly observed in both the groups, but the treatment results were more consistent in cases treated with extraoral distraction. Extraoral device is more capable of advancing the maxilla rather than the intraoral device and easier to place surgically with more ability of vector adjustment postoperatively. Extraoral device is more bulky and less tolerated by

patients as well as causing more complications as regard soft tissue injuries. The amount of postoperative relapse occurred more for cases using extraoral device was directly related to the greater amount of maxillary advancement. Lateral cephalometry is an important diagnostic tool in measuring the amount of maxillary advancement needed preoperatively as well as amount achieved postoperatively besides soft tissue changes and amount of postoperative relapse. Multi slice 3DCT is important for measuring bone density preoperatively and comparing it postoperatively after complete consolidation besides its diagnostic role. Mimics software is a new innovation for preoperative surgical planning and obtaining 3D model which is useful in preoperative adaptation of intraoral device plates, besides saving intra operative time and effort. Hence AMSD could be considered as a better choice of treatment in cases of maxillary hypoplasia associated with cleft lip and palate.

### Acknowledgement

The authors would like to thank the Oral & Maxillofacial Surgery Department, Faculty of Dental Medicine, Al Azhar University for Girls and special thanks to Dr Marwa Abdelwahab El Kassaby Associate Professor at Maxillofacial department, Faculty of Oral & Dental Medicine, Ain Shams University

### References

- [1]. **Hirano A, Suzuki H:** Factors related to relapse after LeFort I maxillary advancement osteotomy in patients with cleft lip and palate. *Cleft Palate Craniofac J* 38:1, 2001
- [2]. **Cheung LK, Chua HD, Ha'gg MB:** Cleft maxillary distraction versus orthognathic surgery: clinical morbidities and surgical relapse. *Plast Reconstr Surg* 118:996, 2006
- [3]. **Cohen SR, Rutrick RE, Burstein FD:** Distraction osteogenesis of the human craniofacial skeleton: initial experience with a new distraction system. *J Craniofac Surg* 6:368, 1995
- [4]. **Cheung LK, Chua HD:** A meta-analysis of cleft maxillary osteotomy and distraction osteogenesis. *Int J Oral Maxillofac Surg* 35:14, 2006
- [5]. **Ilizarov L, Mikhail L:** Biomechanical considerations of mandibular lengthening and widening by gradual distraction using a computer model. *J Oral Maxillofac Surg* 56:51, 1988
- [6]. **Karakasis D and Hadjipetrou L:** Advancement of the anterior maxilla by distraction *J Craniomaxillofac Surg* 32:150, 2004.
- [7]. **Alkana, Baş B, Özer M, Bayram M and Yüzbaş ıo ğlu E:** Maxillary Anterior Segmental Advancement of Hypoplastic Maxilla in Cleft Patients by Distraction Osteogenesis. *J Oral Maxillofac Surg* 66:126, 2008.
- [8]. **Wang X, Li Z, Liang C, Jia Y and Zou B:** Anterior maxillary segmental distraction for correction of maxillary hypoplasia and dental crowding in cleft palate patients. *Int J Oral Maxillofac Surg* 39:1237, 2009.
- [9]. **Zemann Wand Pichelmayr M:** Maxillary segmental distraction in children with unilateral clefts of lip, palate, and alveolus. *J Oral Surg Oral Med* 2: 4 , 2010.
- [10]. **Baek SH, Lee JK, Lee JH, Kim MJ, Kim JR :** Comparison of treatment outcome and stability between distraction osteo- genesis and LeFort 1 osteotomy in cleft patients with maxillary hypoplasia. *J Craniofac Surg* 18:1209, 2007
- [11]. **Chua HD, Ha'gg MB, Cheung LK :** Cleft maxillary distraction versus orthognathic surgery—which one is more stable in 5 years? *Oral Surg Oral Med Oral Pathol Oral Radiol Endod* 109:803, 2010
- [12]. **Aikawa T, Haraguchi S, Tanaka S, Uematsu S, Ishibashi M, Kogo M and Iida S:** Rotational movement of the anterior maxillary segment by hybrid distractor in patients with cleft lip and palate. *J Oral Surg* 110: 292, 2010.
- [13]. **Gunaseelan R, Cheung L, Krishnaswamy R and Veerabahu M:** Anterior Maxillary Distraction by Tooth-Borne Palatal Distractor. *J Orthodontics*. 65: 1044 , 2007.
- [14]. **Okcu K, Sencimen M, Karacay S, Bengi A, Örs F, Dogan N and Gokce H:** Anterior segmental distraction of the hypoplastic maxilla by a tooth borne device: a study on the movement of the segment. *Int J Oral Maxillofac Surg* 38: 817, 2009.
- [15]. **Figueroa AA and Polley JW:** External Versus Internal Distraction Osteogenesis for the Management of Severe Maxillary Hypoplasia: External Distraction *J Oral Maxillofac Surg* 66: 2598 , 2008.
- [16]. **Rachmiel A, Aizenbud D, Peled M** Distraction osteo- genesis in maxillary deficiency using a rigid external distraction. *Plast Reconstr Surg* 117:2399, 2006
- [17]. **Van Sickels J, Madsen M, Cunningham L and Bird D:** The Use of Internal Maxillary Distraction for Maxillary Hypoplasia. A Preliminary Report. *J Oral Maxillofac Surg* 64:1715, 2006
- [18]. **Liou J and Chen K:** Intraoral distraction of segmental osteotomies and miniscrews in management of alveolar cleft. *J Craniofac Ortho* 15:257, 2009.
- [19]. **Troulis MJ, Everett P, Seldin EB, Kikinis R and Kaban LB :** Development of a three-dimensional treatment planning system based on computed tomographic data. *Int J oral Maxillofac Surg* 31:349-357, 2002
- [20]. **Bengi O, Karacay S, Akin E, Okcu K, Ölmez H and Mermut S:** Cephalometric evaluation of patients treated by maxillary anterior segmental distraction. *J Craniomaxillofac Surg* 35:302, 2007.
- [21]. **Rachmiel A:** Treatment of Maxillary Cleft Palate: Distraction Osteogenesis Versus Orthognathic Surgery—Part One: Maxillary Distraction. *Int J Oral Maxillofac Surg* 65 : 753, 2012.
- [22]. **Block M, Brister G:** Use of distraction osteogenesis for maxillary advancement: preliminary results. *J Oral Maxillofac Surg* 52: 28, 1994.
- [23]. **Dolanmaz D, Karaman AI, Ozyesil AG:** Maxillary anterior segmental advancement by using distraction osteogenesis: A case report. *Angle Orthod*. 73: 201, 2003.
- [24]. **Harada K, Baba Y and Ohyama K:** Soft tissue profile changes of the midface in patients with cleft lip and palate following maxillary distraction osteogenesis: A preliminary study. *Oral Surg, Oral Med, Oral Pathol, Oral Radiol, Endod* 94:673, 2002.
- [25]. **Daimaruya T, Imai Y, Kochi S , Tachi M and Yamamoto T:** Midfacial Changes Through Distraction Osteogenesis Using a Rigid External Distraction System With Retention Plates in Cleft Lip and Palate Patients. *J Oral Maxillofac Surg* 68:1480, 2010.
- [26]. **Aksu M, Aydinatay B , Akcan C, Hakan El , Taner T, Kocadereli I , Tunchilek G and Mavili M:** Skeletal and Dental Stability After Maxillary Distraction With a Rigid External Device in Adult Cleft Lip and Palate Patients *J Oral Maxillofac. Surg* 68: 254 , 2010.
- [27]. **Chin M, Toth BA:** Distraction osteogenesis in maxillofacial surgery using internal devices. Review of five cases. *J Oral Maxillofac Surg* 54: 45, 1996.



- [28]. **Diner AP, Galliani E, Tomat C, Vazquez M, Carls F:** Five years experience with a new intraoral maxillary distraction device (RIDBr). *J. Oral Maxillofac. Surg.* 49: 546 , 2011
- [29]. **Bell WH and Epker BN,** Surgical-orthodontic expansion of the maxilla, *Am J Orthod* 70 : 517 , 1976.
- [30]. **Legan HL, Burstone CJ:** Soft tissue cephalometric analysis for orthognathic surgery. *J Oral Surg* 38: 744 , 1980.
- [31]. **Gateno J, Xia J, Taylor T:** Outcome Study of Computer-Aided Surgical Simulation in the Treatment of Patients With Craniomaxillofacial Deformities, *J. oral Maxillofac Surg* 69: 2014, 2011.